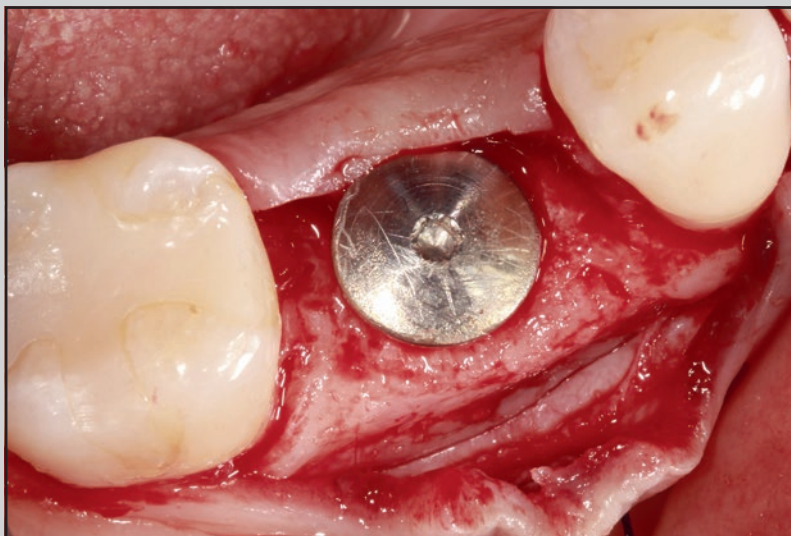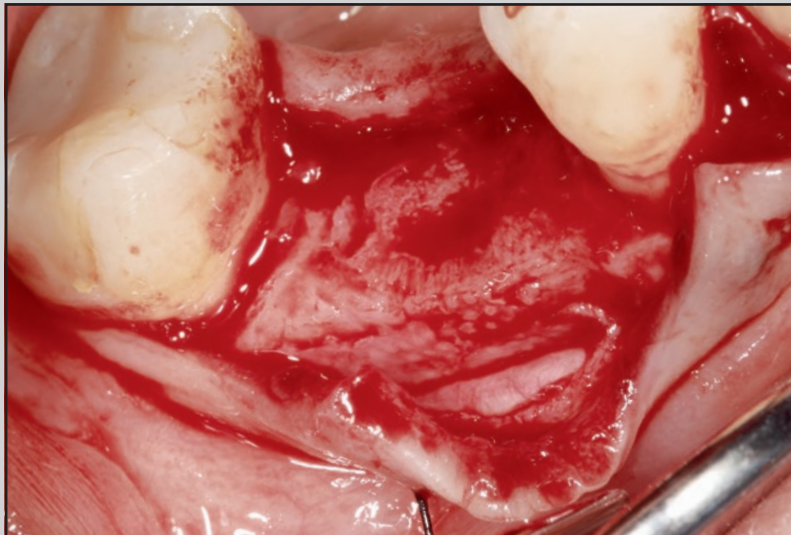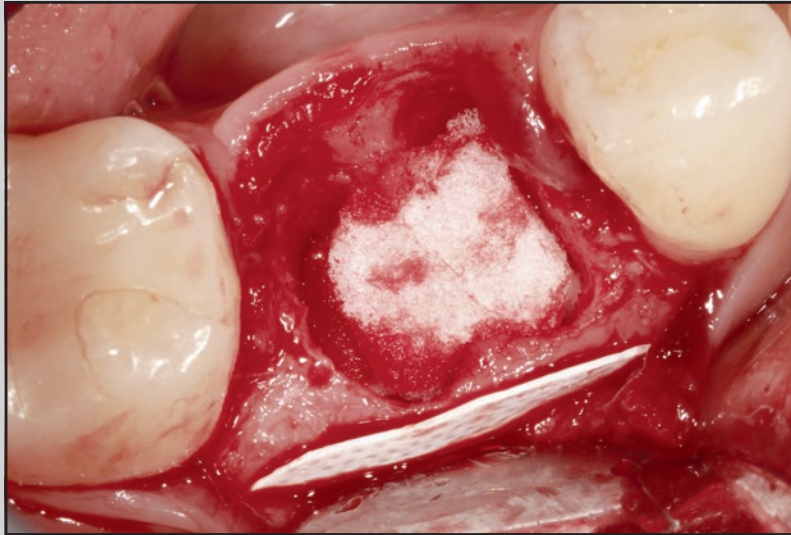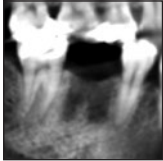


# Periosteal Inhibition Technique for Alveolar Ridge Preservation as It Applies to Implant Therapy



Vinh Nguyen, DDS, MSc<sup>1</sup>  
 Nadine von Krockow, DDS, DMD<sup>2</sup>  
 Joanne Pouchet, BSc, DDS, Dip Perio<sup>3</sup>  
 Paul Martin Weigl, DMD<sup>4</sup>

*Alveolar ridge preservation procedures have been shown to significantly reduce the loss of ridge dimension of an extraction socket. As of yet, none of the alveolar ridge preservation techniques have been proven totally effective in preserving ridge morphology. The Periosteal Inhibition technique for alveolar ridge preservation involves placing a high-density polytetrafluoroethylene (d-PTFE) membrane between the periosteum and the buccal bone plate of an extraction socket. The authors hypothesize that the nonresorbable d-PTFE membrane, because of its much smaller pore diameter as compared to the size of the osteoclast precursor cells, inhibits the migration of the osteoclast precursor cells from the periosteum to the bony surface and, subsequently, their fusion to form osteoclasts. As a result, osteolytic activity on the outer surface of the socket is inhibited. The Periosteal Inhibition technique for alveolar ridge preservation is presented along with immediate implant treatment results using this treatment concept. The resulting stable ridge dimensions in these cases demonstrate a possibility that the d-PTFE membrane may effectively prevent modeling of the extraction socket by inhibiting the formation of osteoclasts on the outer bony surface. Int J Periodontics Restorative Dent 2019;39:737–744. doi: 10.1607/prd.4178*

Alveolar ridge preservation (ARP) procedures have been recommended to help reduce the loss of ridge dimension of an extraction socket.<sup>1–3</sup> All of these procedures involve filling the socket with a bone graft material. In order to contain the graft material, an occlusive barrier such as an autogenous soft tissue graft or resorbable/nonresorbable membrane is often required. As of yet, no one ARP technique has been proven superior to another,<sup>2,3</sup> and none have proven totally effective in preserving ridge morphology.<sup>3–5</sup>

In an animal histologic study in 2005, Araújo and Lindhe demonstrated that trauma and loss of periodontal ligament triggered an osteoclastic activity, causing loss of bundle bone and modeling of the cortical bone plate.<sup>6</sup> Osteoclasts are multinucleated cells that are responsible for bone resorption and are found on the outer layer of bone, beneath the periosteum.<sup>7</sup> They are thought to be derived from pluripotent hematopoietic stem cells.<sup>8,9</sup> When stimulated, these mononuclear precursors, the smallest of which is 9.5  $\mu\text{m}$  in diameter,<sup>10</sup> proliferate and attach to the bone surface to be resorbed, and only then do they fuse to form large, mature multinucleated osteoclasts.<sup>11</sup>

High-density polytetrafluoroethylene (d-PTFE) membranes have been used in ARP procedures as

<sup>1</sup>Private Practice, Quebec, Canada; Faculty of Oral and Dental Medicine, J. W. Goethe-University, Frankfurt am Main, Germany.

<sup>2</sup>Private Practice; Faculty of Oral and Dental Medicine, J. W. Goethe-University, Frankfurt am Main, Germany.

<sup>3</sup>Private Practice, British Columbia, Canada.

<sup>4</sup>Faculty of Oral and Dental Medicine, J. W. Goethe-University, Frankfurt am Main, Germany.

Correspondence to: Dr Vinh Nguyen, 1500 Rome Blvd, Brossard, Quebec J4W 2T4, Canada. Email: email@drvinhnguyen.com

Submitted November 7, 2018; accepted January 31, 2019.

©2019 by Quintessence Publishing Co Inc.

an occlusive barrier to contain the bone graft material.<sup>12</sup> The membrane porosity of less than 0.3  $\mu\text{m}$  is impervious to bacteria and thus is recommended for a socket preservation technique, where a membrane is intentionally exposed.<sup>13</sup>

The Periosteal Inhibition (PI) technique, introduced for the first time in this article, is the only ARP procedure to date targeting the prevention of the osteolytic activity on the external surface of an extraction socket. The technique involves placing a d-PTFE membrane between the periosteum and the buccal bone plate of an extraction socket and leaving it in place for 4 months, the time needed for the completion of bone formation within the socket. The authors hypothesize that the small-diameter pores (0.3  $\mu\text{m}$ ) in the nonresorbable d-PTFE membrane inhibit the passage of the precursor cells (9.5  $\mu\text{m}$ ) from the periosteum to the bone surface. Osteolytic activity on the outer surface of the socket is thereby prevented, as the precursor cells cannot form osteoclasts.

In this case series, the PI technique for ARP will be presented along with immediate implant treatment results using the same treatment concept.

## Materials and Methods

Nine patients were selected for the study (seven ARP procedures and two immediate implant [II] placements), and all patients were healthy with no contributory factors. Specifically, patients who had no active infection present and had an

intact buccal marginal bone were chosen to participate. Specific informed consent was obtained. A single dose of amoxicillin (2 g) was administered 1 hour before surgery. Under local anesthetic, atraumatic extractions were performed in order to minimize the alteration of the marginal bone. Extraction sockets were thoroughly debrided. Unless specified in the description of an individual case, the PI surgical procedure was performed in an identical fashion for both the ARP and II treatments, described as follows:

Using a #69 Nordland microblade, a sulcular incision was performed around the tooth to be extracted and also on the buccal sulcus of adjacent teeth. A conservative full-thickness envelope flap was elevated on the buccal side, extending from the mesiobuccal line angle of the distal tooth to the distobuccal line angle of the mesial tooth adjacent to the tooth to be removed. This extension allows visual inspection of the buccal bone plate thickness and condition. A thin periosteal elevator was used to detach buccal periosteum from the buccal bone to extend the flap more apically. The d-PTFE membrane (Cytoplast TXT-200 Single, Osteogenics) was trimmed to a height of 8 to 10 mm and a width great enough to cover the buccal bone plate between the proximal line angles of the extraction socket. The membrane corners were rounded to minimize membrane exposure. The membrane was inserted between the bone and the periosteum and secured to the buccal flap with a thin, nonresorbable monofilament suture. An absorb-

able gelatin sponge (Spongostan, Johnson & Johnson) was inserted in the extraction socket to help stabilize the blood clot.

In II cases, the gelatin sponge was placed between the implant and the buccal bone. These two II cases obtained a minimum torque of 35 Ncm, allowing the installation of a screw-retained provisional crown.

Membranes were removed at 4 months postoperative for all cases.

A template and ridge-mapping caliper were used to measure the preoperative and postoperative midfacial ridge width at 3 mm apical to the preoperative gingival margins for the seven ARP cases. Data for the seven ARP cases and two II cases are presented in Table 1. At 4 months postextraction, cone beam computed tomography (CBCT) images confirmed the stable dimensions of the PI technique for ridge preservation (Fig 1).

## Socket Preservation

### Case 1

A 42-year-old woman required the removal of a carious nonrestorable mandibular right first molar. An ARP procedure using the PI technique for delayed implant placement was selected. A surgical stent was used as reference to record midfacial ridge dimensions at the time of surgery and at reentry surgery. The surgical procedure was performed as previously described, with a small full-thickness envelope flap elevated on the buccal side.

**Table 1** Difference Between Pre- and Postextraction Ridge Widths

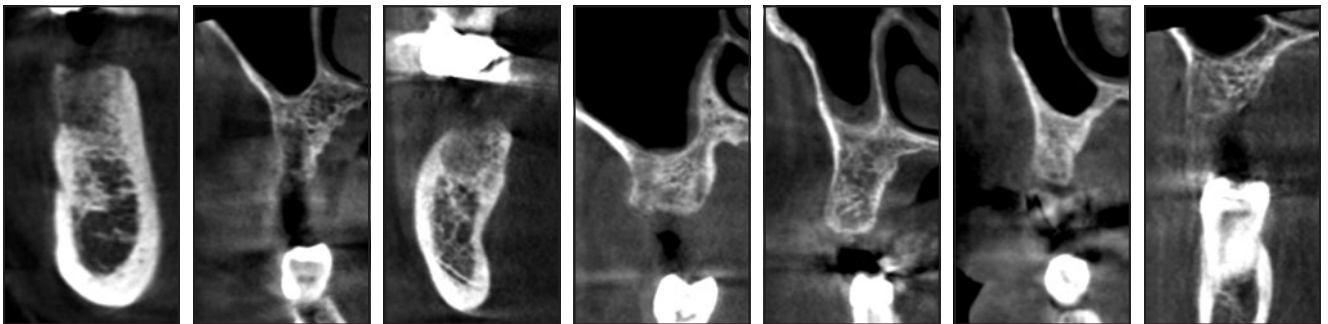
Cases, no.	Tooth no. (FDI system)	Initial buccal bone thickness (mm)	Soft tissue ridge width (mm)			Bony ridge width (mm)		
			Preoperative	Postoperative	$\Delta$	Preoperative	Postoperative	$\Delta$
<b>RP cases<sup>a</sup></b>								
1	46	0.5	12.5	12.5	0	11	11	0
2	15	1.5	11	11	0	8	8	0
3	37	0.5	12.5	12	0.5	10	10	0
4	16	0.5	14	13.5	0.5	11	11	0
5	24	1.5	12	11.5	0.5	9	9	0
6	14	1.0	12	11	1	8	7	1
7	26	1.0	12	11.5	0.5	9	8.5	0.5
Mean RP		0.9	12.3	11.9	0.4	9.4	9.2	0.2
SD		0.4	0.9	0.9	0.3	1.3	1.5	0.4
<b>II cases<sup>b</sup></b>								
8	13	0.5	10	10	0	7.5	7.5	0
9	24	0.5	12	11.5	0.5	9.5	9	0.5
Mean II		0.5	11.0	10.8	0.3	8.5	8.3	0.3
SD		0	1.4	1.1	0.4	1.4	1.1	0.4

RP = ridge preservation; SD = standard deviation; II = immediate implant.

Measurements were taken at the midfacial position, 3 mm apical to the gingival margin, and rounded to the closest 0.5 mm.

<sup>a</sup>Postoperative measurements taken at 4 months after implant placement.

<sup>b</sup>Postoperative measurements taken at 15 months after implant placement.



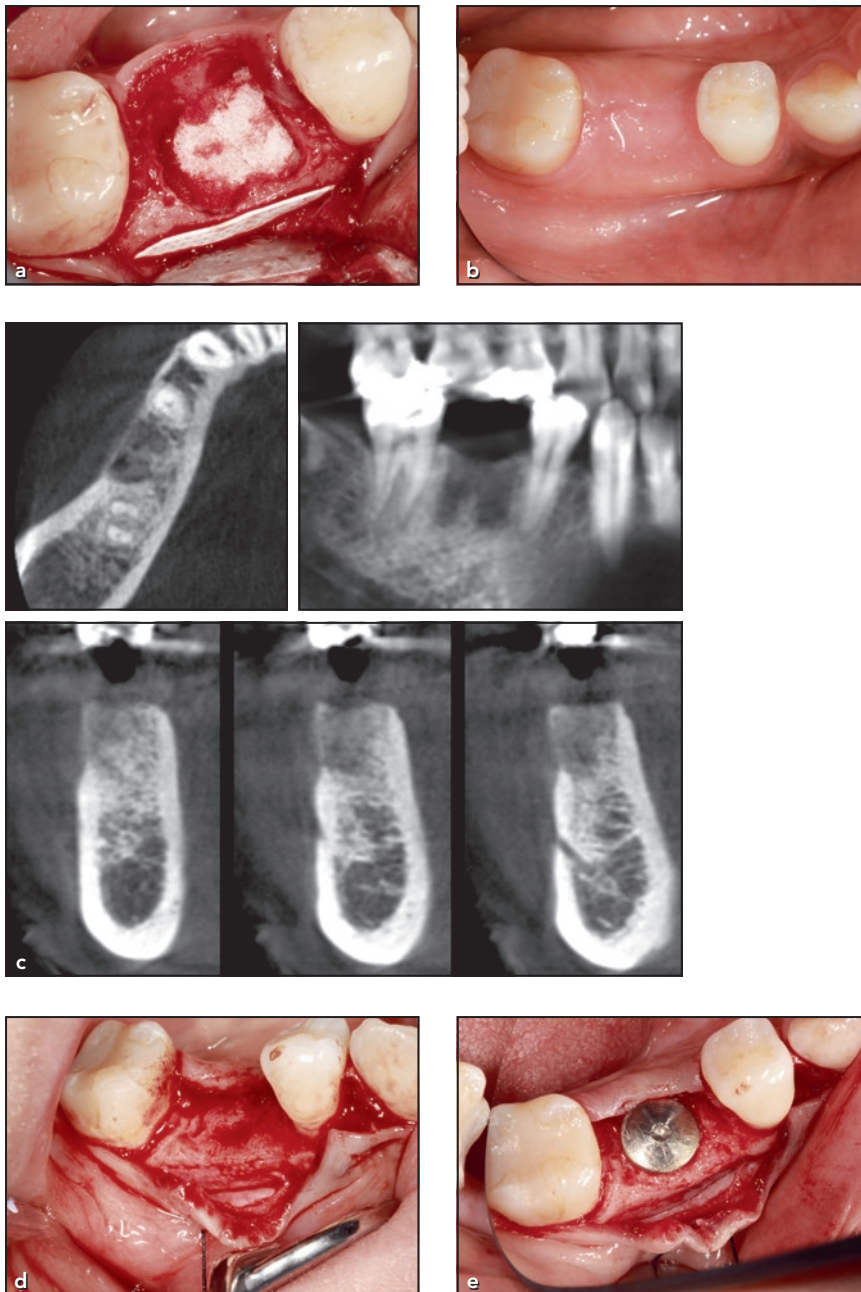
**Fig 1** CBCT images of the seven ridge preservation cases (patients 1 to 7, shown consecutively) taken at 4 months postextraction.

The tooth was carefully removed, revealing the buccal bone to be less than 0.8 mm thick. Spongostan was placed in the socket, and a piece of d-PTFE membrane (8 × 10 mm) was inserted between the periosteum and the buccal bone. The textured surface of the membrane with the hex-shaped dimples was placed against the bone surface while the smooth surface of the membrane faced the periosteum

(Fig 2a). The coronal margin of the membrane was positioned at the level of buccal bone margin, thus allowing complete submergence of the membrane after flap closure. To secure the d-PTFE membrane and to close the flap, simple interrupted PTFE sutures passed through the mesial and distal corners of the d-PTFE membrane along with the flap edges. The patient was seen at 1 week for assessment and at 2 weeks

for suture removal. Thereafter, the patient was seen once a month to check for signs of early membrane exposure.

At 4 months postextraction, the soft tissue ridge dimension was stable (Fig 2b) and a CBCT scan showed well-preserved buccal bone plate (Fig 2c). A full-thickness envelope flap was then raised to remove the membrane and visualize the preserved ridge. The patient's



**Fig 2** Patient 1. (a) The d-PTFE membrane was inserted under the flap between the buccal bone and the periosteum of the extraction socket of the mandibular right first molar. (b) Ridge profile at the mandibular first molar site at 4 months postoperative, before reentry and implant placement. (c) The CBCT scan taken at 4 months postextraction shows a well-preserved buccolingual ridge dimension at the molar. (d) The appearance of the preserved ridge. Note the new bone formation on the buccal surface, which follows the hex-shaped dimple configuration of the membrane surface, forming little bone nodules. The 90-degree angle between the buccal and occlusal surfaces demonstrates bone forming up to the coronal edge of the membrane. (e) Healing abutment in place. Note the appearance of the well-preserved ridge.

extraction socket appeared to be completely filled with good-quality hard bone. Both soft tissue and bone widths maintained their original dimensions, while the midfacial bone height showed an increase of 1 mm compared to the preoperative measure. The occlusal surface

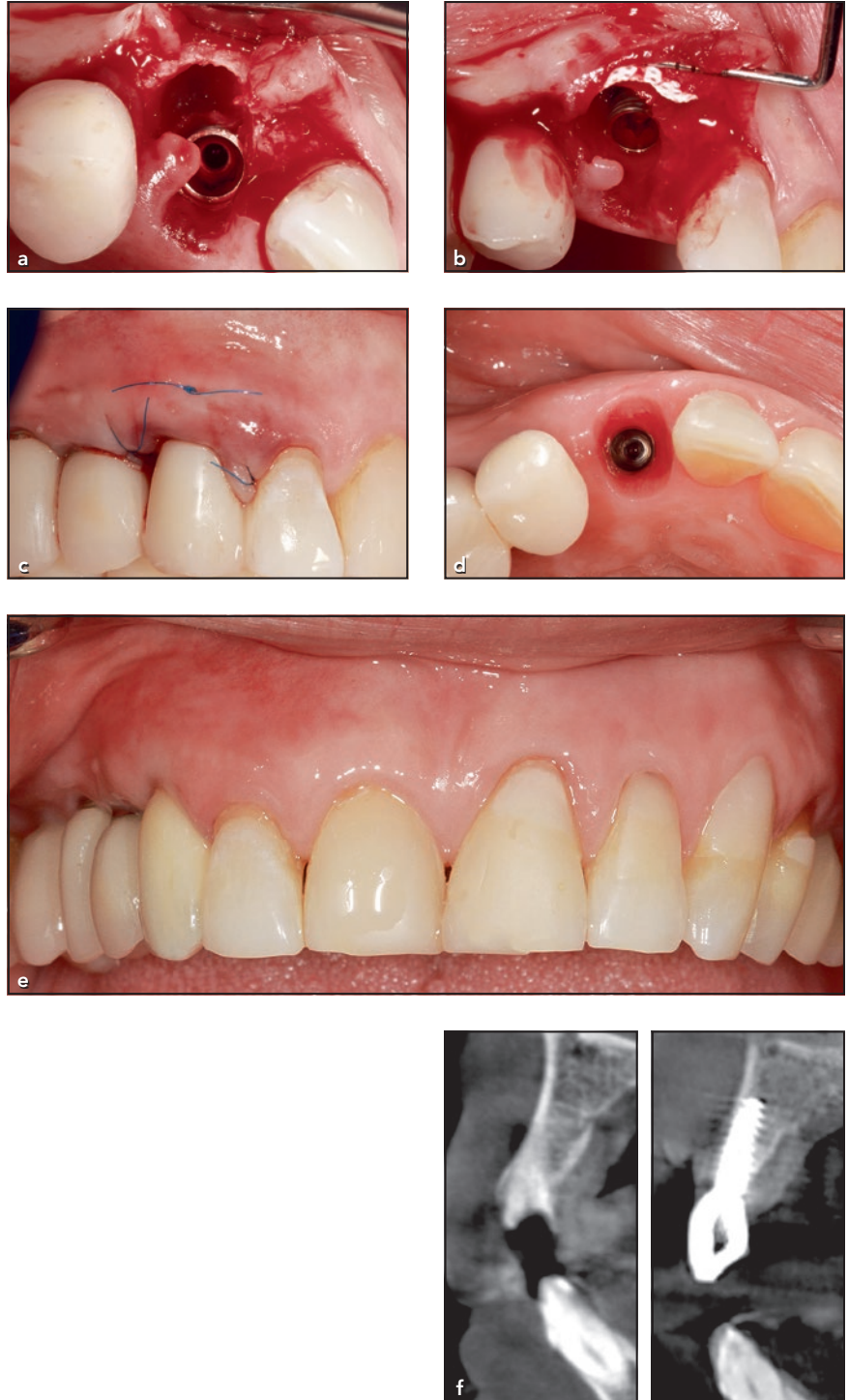
of the ridge had a flat appearance, forming a 90-degree angle to the buccal bone surface. Interestingly, new bone formation was observed in the shape of small bony nodules on the buccal surface, following the hex-shaped dimple configuration of the membrane surface (Fig 2d).

An osteotomy was prepared, and a Straumann tissue-level Standard Implant (SLActive; wide neck, 4.8 × 10 mm) was inserted achieving 35 Ncm torque (Fig 2e). The final screw-retained crown was delivered 3 months after implant placement.

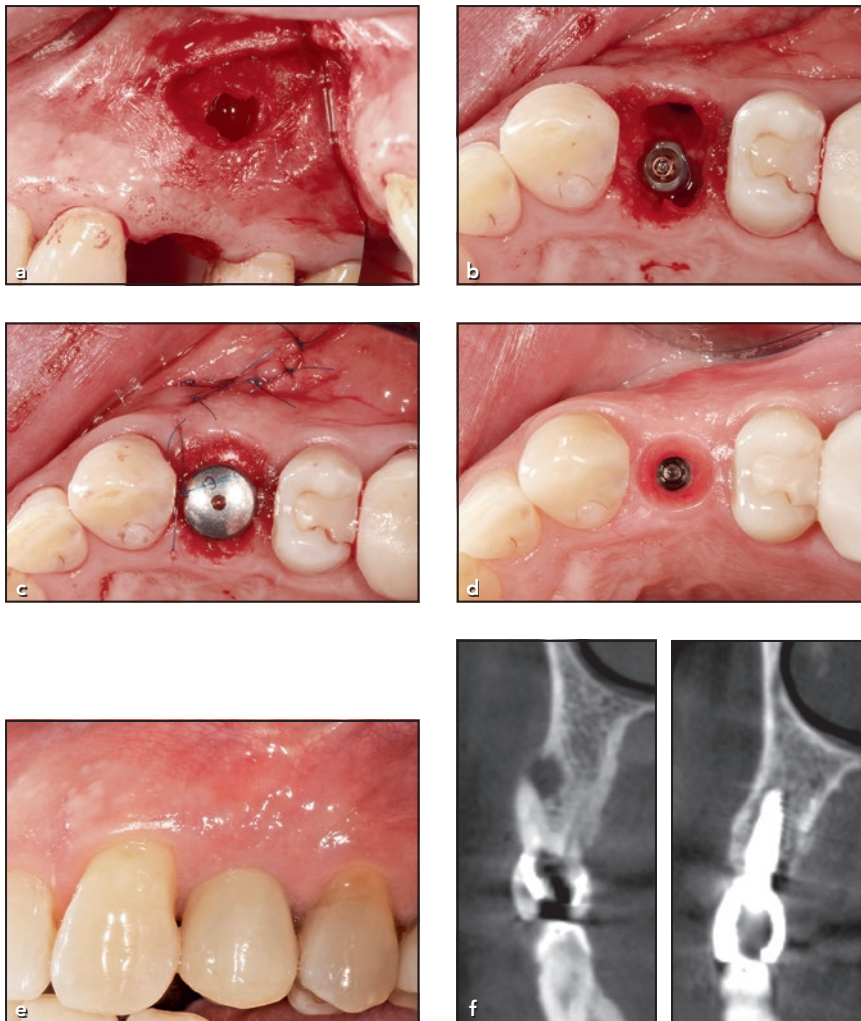
## Immediate Implant Placement

### Case 8

A 64-year-old woman required an II placement in the maxillary right canine site. The tooth was not salvageable due to a vertical root fracture. The root was removed, and a 3.5 × 13-mm NobelActive implant (Nobel Biocare) was placed palatally, leaving 2.5 mm of buccal space. An envelope flap was raised, revealing 0.3 mm of buccal bone thickness (Fig 3a), which had a very prominent curvature. The d-PTFE membrane was trimmed as previously described and inserted under the full-thickness flap, closely following the curvature of the very thin buccal bone (Fig 3b). The membrane was sutured to the buccal flap using a horizontal mattress suture. A screw-retained temporary crown was fabricated using a temporary abutment and a polycarbonate temporary crown lined with flowable composite. Two simple interrupted interproximal sutures were used to close the flap (Fig 3c). At 4 months after implant placement, under local anesthetic, the d-PTFE membrane was removed through a small incision made in the buccal vestibule. The final impression was taken, and a screw-retained final crown was delivered (Figs 3d and 3e). At 12 months after crown installation, the buccal ridge contour appeared stable; preoperative and 16-month postoperative CBCT cross-sectional images demonstrate insignificant ridge alteration at the implant site (Fig 3f). The CBCTs, taken postoperatively for both Case 8 and Case 9, were incidentally required for the



**Fig 3** Patient 8. (a) In this II case, an envelope flap was raised, revealing a thin buccal bone plate of the extraction socket of the maxillary right canine. An implant was inserted, leaving 2.5 mm of buccal space. (b) The d-PTFE membrane was inserted between the buccal bone and the full-thickness flap. (c) The membrane was secured to the buccal flap using a horizontal mattress suture, and the flap was closed with two simple interrupted proximal sutures. (d) Soft tissue profile just before the placement of the final crown. (e) The final screw-retained crown was placed on the treated maxillary right canine. (f) Preoperative and 16-month postoperative CBCTs demonstrate insignificant ridge alteration at the implant site.



**Fig 4** Patient 9. (a) Apical surgery was performed at the time of extraction to debride the periapical granulomatous lesion that had formed a fenestration on the buccal bony plate of the maxillary left first premolar. (b) An Ankylos implant ( $3.5 \times 10$  mm) was placed in the interdental bone, leaving a 3-mm empty buccal root socket. (c) After the d-PTFE membrane had been sutured to the buccal flap and an absorbable gelatin sponge was placed in the buccal space, a healing abutment was placed. The flap for the apical surgery was also closed using polypropylene sutures. (d) Occlusal view of the ridge at the final impression appointment. (e) Lateral view of the final screw-retained crown on the implant at the premolar site. (f) Preoperative and 15-month postoperative CBCTs demonstrate insignificant ridge alteration at the implant site.

planning of another implant placement in a different region of the patients' mouths.

#### Case 9

Failed endodontic retreatment necessitated the removal of the maxillary left first premolar of a 58-year-old man. After the tooth was extracted, a semilunar incision was made in the vestibular mucosa and a flap was reflected to expose the periapical granulomatous lesion that had formed a fenestration on the buccal bony plate (Fig 4a). The

lesion was thoroughly debrided, and an Ankylos implant ( $3.5 \times 10$  mm; Dentsply Sirona) was placed in the interdental bone, leaving a 3-mm empty buccal root-socket space (Fig 4b). A small amount of Bio-Oss (Geistlich Pharma) was placed within the confinement of the apical bone defect only, and apical flap closure was done using simple interrupted sutures. A buccal full-thickness envelope flap was prepared, and a piece of d-PTFE membrane was inserted between the periosteum and the buccal bone as described

previously. A horizontal mattress suture secured the d-PTFE membrane to the buccal envelope flap. Spongostan was placed in the buccal socket, and a healing abutment was placed (Fig 4c). Four months after implant placement, the d-PTFE membrane was removed through a small incision made in the buccal vestibule in the same manner mentioned in Case 8. The ridge dimension appeared stable (Fig 4d), and a screw-retained crown was fabricated and delivered (Fig 4e). Preoperative and 15-month postoperative

CBCT cross-sectional images demonstrate insignificant ridge alteration at the implant site (Fig 4f).

## Discussion

Various ARP techniques have been introduced to lessen dimensional alterations of extraction sockets, including utilizing bone substitutes as scaffolding to minimize alterations.<sup>14–16</sup> Although these procedures have been proven effective in preserving the alveolar bone for subsequent implant placement, they do not completely prevent dimension shrinkage,<sup>2,3</sup> and thus additional tissue augmentation is often necessary to fully restore ridge dimension, especially in the esthetic regions. In addition, with the exception of a polylactide/polyglycolide sponge<sup>17</sup> and calcium sulphate,<sup>18</sup> a high percentage of residual non-vital graft materials are found in the grafted sites.<sup>15,19</sup> Although this does not affect the stability of an implant, the long-term effect of residual ridge-preservation materials on implant survival still needs to be investigated. Cost of materials, long waiting times due to the slow turnover rate of bone substitute materials, and additional augmentation procedures are general drawbacks of these techniques. The PI technique preliminarily appears to overcome these disadvantages by effectively preserving ridge dimension without resorting to the use of bone grafting materials. The insignificant changes in ridge dimension observed with the PI technique presented in Table 1 show that ARP

can be achieved with a d-PTFE membrane placed on the buccal ridge of the extraction socket while leaving sockets to heal with a blood clot alone. While conventional ARP procedures focus on promoting bone fill within the socket, the PI technique is the only nonaugmenting procedure that addresses the source of bone modeling from the outer bone wall: osteoclasts. The bone formation underneath the d-PTFE membrane, which appears to follow the hex-shaped dimple configuration of the membrane surface (seen in Case 1), is an indication that there is a lack of osteoclastic activity on the outer surface of the buccal bone plate. An absorbable gelatin sponge was used in the present study to obliterate the socket space and to hold the blood clot in place; it is completely resorbed in 4 to 6 weeks and is known not to promote bone formation.<sup>20,21</sup> Concurrently, pure native bone formed within the socket from the blood clot alone is a great advantage of the PI technique in providing an implant placement with a high ratio of native bone to implant contact.

Studies have demonstrated that an II placement does not prevent the collapse of the buccal bone wall.<sup>22–24</sup> Thus, as in ARP procedures, bone grafting has been recommended in II placement to fill the space between an implant and the buccal bone. In the present article, this was not seen in II placements using the PI technique. In the II cases presented in this article, only a blood clot was allowed to form in a large buccal gap. Together, with very thin existing buccal walls

as observed in Cases 8 and 9, this would have resulted in significant loss in ridge morphology.<sup>25,26</sup> Ridge dimensions in Cases 8 and 9 observed 16 months after the II placement appear stable.

## Conclusions

The resulting stable ridge dimensions in this case series using the PI technique for ARP and II placement demonstrate a strong possibility that the d-PTFE membrane may effectively prevent modeling of the extraction socket by inhibiting the formation of osteoclasts on the outer bony surface. Further studies are needed to support the application of the PI technique in routine clinical practice.

## Acknowledgments

The authors report no conflicts of interest related to this article.

## References

1. Walker CJ, Prihoda TJ, Mealey BL, Lasho DJ, Noujeim M, Huynh-Ba G. Evaluation of healing at molar extraction sites with and without ridge preservation: A randomized controlled clinical trial. *J Periodontol* 2017;88:241–249.
2. MacBeth N, Trullenque-Eriksson A, Donos N, Mardas N. Hard and soft tissue changes following alveolar ridge preservation: A systematic review. *Clin Oral Implants Res* 2017;28:982–1004.
3. Iocca O, Farcomeni A, Pardiñas Lopez S, Talib HS. Alveolar ridge preservation after tooth extraction: A Bayesian Network meta-analysis of grafting materials efficacy on prevention of bone height and width reduction. *J Clin Periodontol* 2017; 44:104–114.



4. Horváth A, Mardas N, Mezzomo LA, Needleman IG, Donos N. Alveolar ridge preservation. A systematic review. *Clin Oral Investig* 2013;17:341–363.
5. Willenbacher M, Al-Nawas B, Berres M, Kämmerer PW, Schiegnitz E. The effects of alveolar ridge preservation: A meta-analysis. *Clin Implant Dent Relat Res* 2016;18:1248–1268.
6. Araújo MG, Lindhe J. Dimensional ridge alterations following tooth extraction. An experimental study in the dog. *J Clin Periodontol* 2005;32:212–218.
7. Hakeda Y, Kumegawa M. Osteoclasts in bone metabolism [in Japanese]. *Kaibogaku Zasshi* 1991;66:215–225.
8. Hagenaaers CE, van der Kraan, Kawilarang-de Hass EW, Visser JW, Nijweide PJ. Osteoclast formation from cloned pluripotent hemopoietic stem cells. *Bone Miner* 1989;6:179–189.
9. Buckwalter JA, Glimcher MJ, Cooper RR, Recker R. Bone biology. I: Structure, blood supply, cells, matrix, and mineralization. *Instr Course Lect* 1996;45:371–386.
10. Wagner JE, Collins D, Fuller S, et al. Isolation of small, primitive human hematopoietic stem cells: Distribution of cell surface cytokine receptors and growth in SCID-Hu mice. *Blood* 1995;86:512–523.
11. Baron R, Neff L, Tran van P, Nefussi JR, Vignery A. Kinetic and cytochemical identification of osteoclast precursors and their differentiation into multinucleated osteoclasts. *Am J Pathol* 1986;22:363–378.
12. Hoffmann O, Bartee BK, Beaumont C, Kasai A, Deli G, Zafropoulos GG. Alveolar bone preservation in extraction sockets using non-resorbable dPTFE membranes: A retrospective non-randomized study. *J Periodontol* 2008;79:1355–1369.
13. Laurito D, Cugnetto R, Lollobrigida M, et al. Socket preservation with d-PTFE membrane: Histologic analysis of the newly formed matrix at membrane removal. *Int J Periodontics Restorative Dent* 2016;36:877–883.
14. Iasella JM, Greenwell H, Miller RL, et al. Ridge preservation with freeze-dried bone allograft and a collagen membrane compared to extraction alone for implant site development: A clinical and histologic study in humans. *J Periodontol* 2003;74:990–999.
15. Camargo PM, Lekovic V, Carmio J, Kenney EB. Alveolar bone preservation following tooth extraction: A perspective of clinical trials utilizing osseous grafting and guided bone regeneration. *Oral Maxillofac Surg Clin North Am* 2004;16:9–18.
16. Nevins M, Camelo M, De Paoli S, et al. A study of the fate of the buccal wall of extraction sockets of teeth with prominent roots. *Int J Periodontics Restorative Dent* 2006;26:19–29.
17. Serino G, Biancu S, Iezzi G, Piattelli A. Ridge preservation following tooth extraction using a polylactide and polyglycolide sponge as space filler: A clinical and histological study in humans. *Clin Oral Implants Res* 2003;14:651–658.
18. Guamieri R, Aldini NN, Pecora G, Fini M, Giardino R. Medial-grade calcium sulfate hemihydrate (surgiplaster) in healing of human extraction sockets—histologic observation at 3 months: A case report. *Int J Oral Maxillofac Implants* 2005;20:636–641.
19. Artzi Z, Tal H, Dayan D. Porous bovine bone mineral in healing of human extraction sockets. Part 1: Histomorphometric evaluations at 9 months. *J Periodontol* 2000;71:1015–1023.
20. Nappi JF, Lehman JA Jr. The effects of Surgicel on bone formation. *Cleft Palate J* 1980;17:291–296.
21. Armstrong JK, Han B, Kuwahara K, et al. The effect of three hemostatic agents on early bone healing in an animal model. *BMC Surg* 2010;10:37.
22. Araújo MG, Sukekava F, Wennström JL, Lindhe J. Ridge alterations following implant placement in fresh extraction sockets: An experimental study in dogs. *J Clin Periodontol* 2005;32:645–652.
23. Sanz M, Cecchinato D, Ferrus J, Pjetursson EB, Lang NP, Lindhe J. A prospective randomized-controlled clinical trial to evaluate bone preservation using implants with different geometry placed into extraction sockets in the maxilla. *Clin Oral Implants Res* 2010;21:13–21.
24. Sanz M, Lindhe J, Alcaraz J, Sanz-Sanchez I, Cecchinato D. The effect of placing a bone replacement graft in the gap at immediately placed implants: A randomized clinical trial. *Clin Oral Implants Res* 2017;28:902–910.
25. Chappuis V, Engel O, Shahim K, Reyes M, Katsaros C, Buser D. Soft tissue alterations in esthetic postextraction sites: A 3-dimensional analysis. *J Dent Res* 2015;94(suppl 9):s187–s193.
26. Chappuis V, Engel O, Reyes M, Shahim K, Nolte LP, Buser D. Ridge alterations post-extraction in the esthetic zone: A 3D analysis with CBCT. *J Dent Res* 2013;92(suppl 12):s195–s201.